



**PATIENT**

Henry Gayle

**SPECIES**

Canine

**BREED**

Jack Russell Terrier

**SEX**

Male Neutered

**AGE**

12 years

**WEIGHT**

14.1lbs

**INTERPRETED BY**

Maggie Machen Lamy,  
DVM, DACVIM  
(Cardiology)

**IMAGING PERFORMED BY**

Meredith Swart, DVM

**HOSPITAL NAME**

Swart Veterinary  
Imaging

**REFERRING VET**

Dr. Swart

**INVOICE**

46277

**DATE**

12/19/25

**PRESENTING CLINICAL SIGNS**

History: Seen for coughing, syncope, etc. associated with murmur.

**RADIOGRAPHIC FINDINGS** \*NOTE: Images submitted for supplemental cardiac information only.

Significant cardiomegaly, equivocal for CHF.

**ECHOCARDIOGRAM FINDINGS**

2D, m-mode, color flow and doppler imaging is available. The mitral valve is thickened with prolapse into the left atrial lumen. There is severe eccentric mitral regurgitation present. The MR velocity is normal. There is severe left atrial enlargement. There is moderate left ventricular dilation. Left ventricular systolic function is hyperdynamic. There is normal systolic flow velocity across the aortic valve. The aortic valve appears trileaflet with normal mobility. The main pulmonary artery is mildly dilated. Moderate right atrial and right ventricular dilation. The tricuspid valve is thickened with severe tricuspid regurgitation. Elevated TR velocity consistent with significant pulmonary hypertension. Mild pulmonic and aortic insufficiency. Small volume pericardial effusion. No pleural effusion or cardiac masses are seen. Hepatic congestion on subcostal views.

**CARDIAC CHART**

CANINE CARDIAC PARAMETERS	MR VMAX (m/s)	TR VMAX (m/s)	LA/AO (Boon method)	LA/AO (Heart Base; Swe)	FS (%)	EF (%)	EPSS (cm)
NORMAL PARAMETER	4.5-5.5	<2.7	1.3	<1.6	28-40	40-100	<0.6
PATIENT	5.5	4.2	2.9	2.5	44	80	0.3
CANINE CARDIAC PARAMETERS	HR (BPM)	AV VMAX (m/s)	PV MAX (m/s)	BODY WEIGHT (kg)	LA 2D short axis Base view (cm)	LVIDd Avg; 2D and m-mode short axis (cm)	LVIDs Avg; 2D and m-mode short axis (cm)
NORMAL PARAMETER	50-100	0.7-1.7	0.7-1.6	BELOW	BELOW	BELOW	BELOW
PATIENT		1.6	1.1	6.4	3.2	3.6	2.0
*Normal chamber parameters expressed as a mean value (SD)				3	1.27 (5.3)	2.46 (2.46)	1.36 (5.5)
<b>BODY WEIGHT DEPENDENT PARAMETERS</b>				5	1.40 (4.5)	2.74 (5.2)	1.60 (4.7)
*Note: All measurements based upon multi-modal images and methods. An average value is reported.				10	1.50 (3.8)	3.27 (3.5)	2.06 (3.1)
				15	1.83 (2.0)	3.71 (2.4)	2.43 (2.1)
				20	2.02 (1.9)	4.14 (2.2)	2.80 (2.0)
Adapted from June Boon, Veterinary Echocardiography, 1998				25	2.18 (2.4)	4.48 (2.9)	3.10 (2.5)
Rishniw M and Hollis NE, J Vet Intern Med 2000; 14:429-435				30	2.33 (3.3)	4.83 (3.9)	3.39 (3.4)
Hansson et al, Vet Rad and Ultrasound 2002				35	2.48 (4.3)	5.17 (5.0)	3.69 (4.5)
Bonagura et al. Echocardiography: principles of interpretation, Vet Clin North Am 15:1177, 1995				40	2.62 (5.2)	5.48 (6.1)	3.96 (5.4)
				50	2.88 (7.1)	6.07 (8.3)	4.46 (7.4)

**INTERPRETATION OF THE FINDINGS & FURTHER RECOMMENDATIONS**

Chronic degenerative valve disease causing severe mitral and tricuspid regurgitation. Severe left atrial and ventricular enlargement indicates the risk for spontaneous left-sided congestive heart failure is elevated. Additionally, there is significant pulmonary hypertension present, which puts the patient at risk for right-sided congestion, and/or **syncope**. The finding of pericardial effusion likely reflects just that, and full lifelong cardiac supportive medications including diuretics and



## PATIENT

Henry Gayle

## SPECIES

Canine

## BREED

Jack Russell Terrier

## SEX

Male Neutered

## AGE

12 years

## WEIGHT

14.1lbs

## INTERPRETED BY

Maggie Machen Lamy,  
DVM, DACVIM  
(Cardiology)

## IMAGING PERFORMED BY

Meredith Swart, DVM

## HOSPITAL NAME

Swart Veterinary  
Imaging

## REFERRING VET

Dr. Swart

## INVOICE

46277

## DATE

12/19/25

Sildenafil are recommended as below. A left atrial tear would be an alternative explanation; however, this is less likely given concurrent hepatic congestion.

Omega fatty acid supplementation and mild salt restriction may also be of some long-term benefit. Monitor for development of a worsening cough, labored breathing, exercise intolerance or worsening collapse episodes. Monitoring of sleeping breathing rates is recommended as the best way to screen for progression to CHF at home. Unfortunately, there is high risk for spontaneous CHF, worsening cough and/or malignant arrhythmias and sudden death in the future. The prognosis with this degree of disease is poor, with most dogs able to maintain a good QOL on medications for an average of 8-12 months.

Elective anesthesia is not advised.

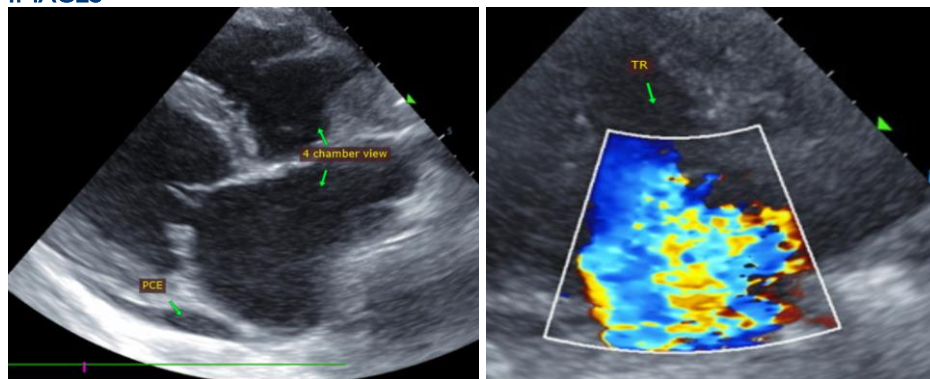
## PLAN

Consider hospitalization if needed for stabilization. Discharge on the following oral medications: institute Furosemide 1-2mg/kg PO q12h. Institute Pimobendan 0.3mg/kg PO q12h. Institute Spironolactone 1-2mg/kg PO q12h. Institute Sildenafil 1-2mg/kg PO q8h. Baseline BP recommended, if >130mmHg institute ACE-I 0.5mg/kg PO q12h.

Recheck renal values and BP in 1-2 weeks, then every 3-4 months on diuretic therapy.

A recheck echocardiogram is recommended in 6 months to screen for progression, sooner if clinical signs arise.

## IMAGES



The information and recommendations provided are based on the images presented by the referring veterinarian. No evaluation can be communicated regarding pathology that was not visible in the image/video clips provided.

Thank you for this referral. This report was generated using transcription software, and minor dictation errors may be present. If the clinical or image interpretation does not parallel your findings or if I can be of any further assistance, please contact me.

Maggie Machen Lamy, DVM

Diplomate of the American College of Veterinary Internal Medicine (Cardiology)

info@sonopath.com